

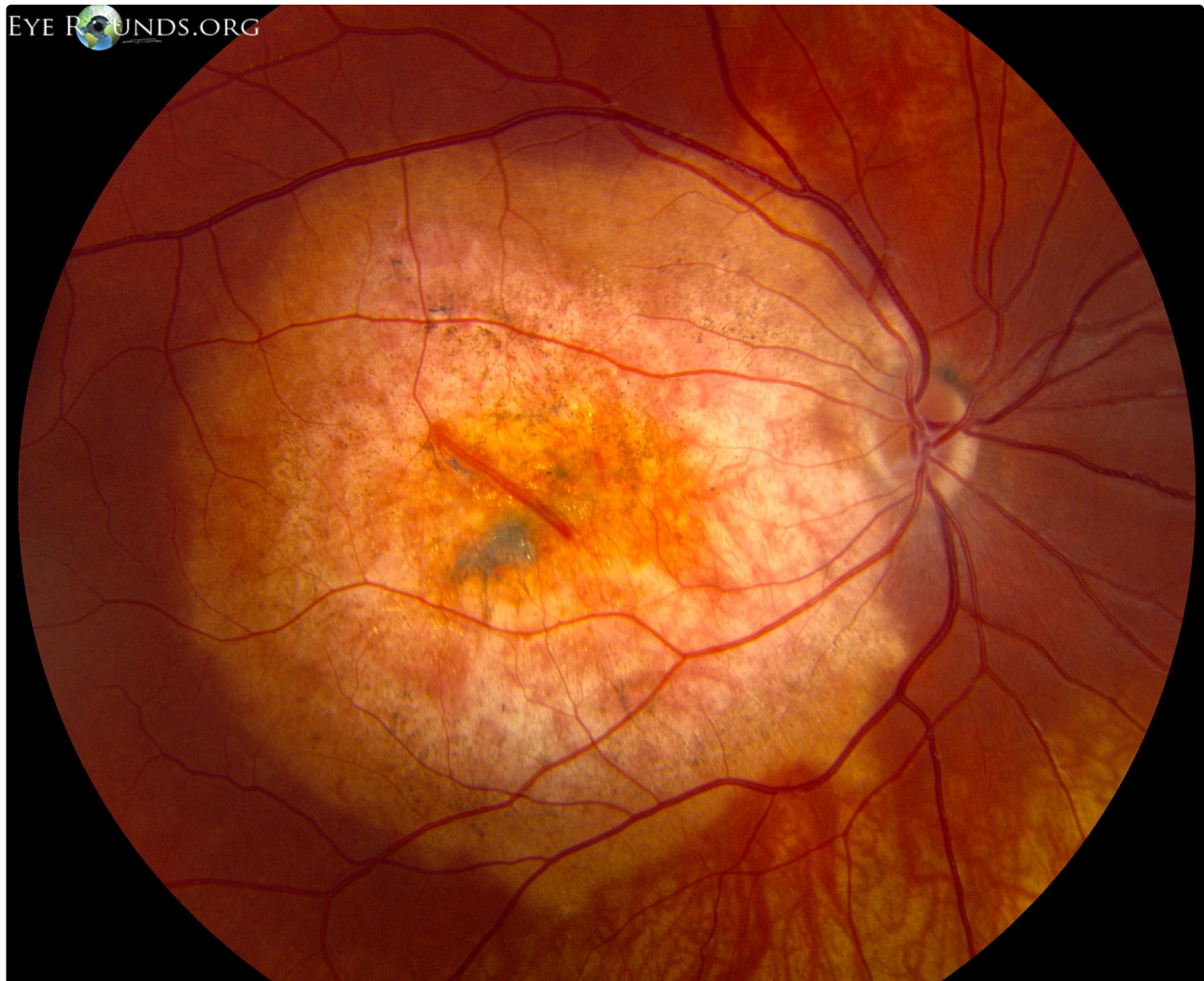
Choroidal osteoma

Category(ies): Retina, Vitreous

Contributor: [Jesse Vislisel, MD](#)

Photographer: Brice Critser, CRA

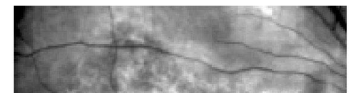

Choroidal osteomas are benign neoplasms in which areas of the choroid are replaced with mature bone. The tumors are most commonly solitary, unilateral, and juxtapapillary in location which helps differentiate them from idiopathic [sclerochoroidal calcification](#). They appear clinically as ovoid subretinal lesions, ranging from yellow-white to orange-red in color, sometimes with overlying pigmentary changes.

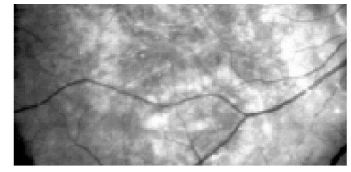
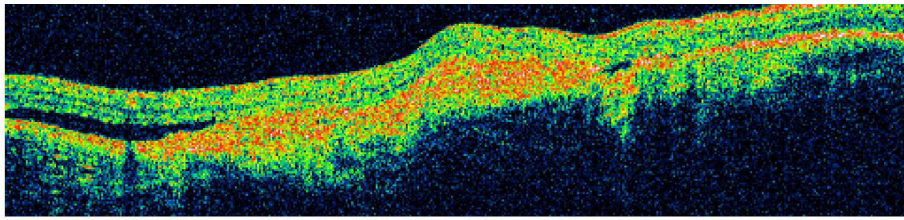


An individual with a choroidal osteoma beneath the macula in the right eye.

 Enlarge

 Download



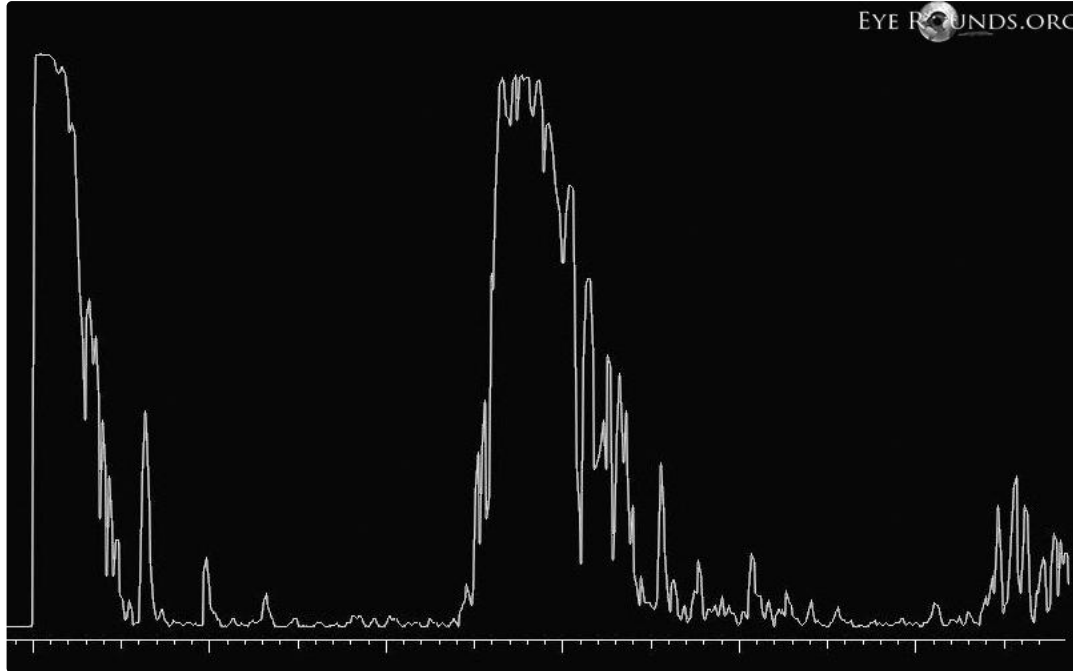


EYE ROUNDS.ORG

OCT scan portrays a highly-reflective lesion at the level of the choroid with associated subretinal fluid.

[Enlarge](#)

[Download](#)

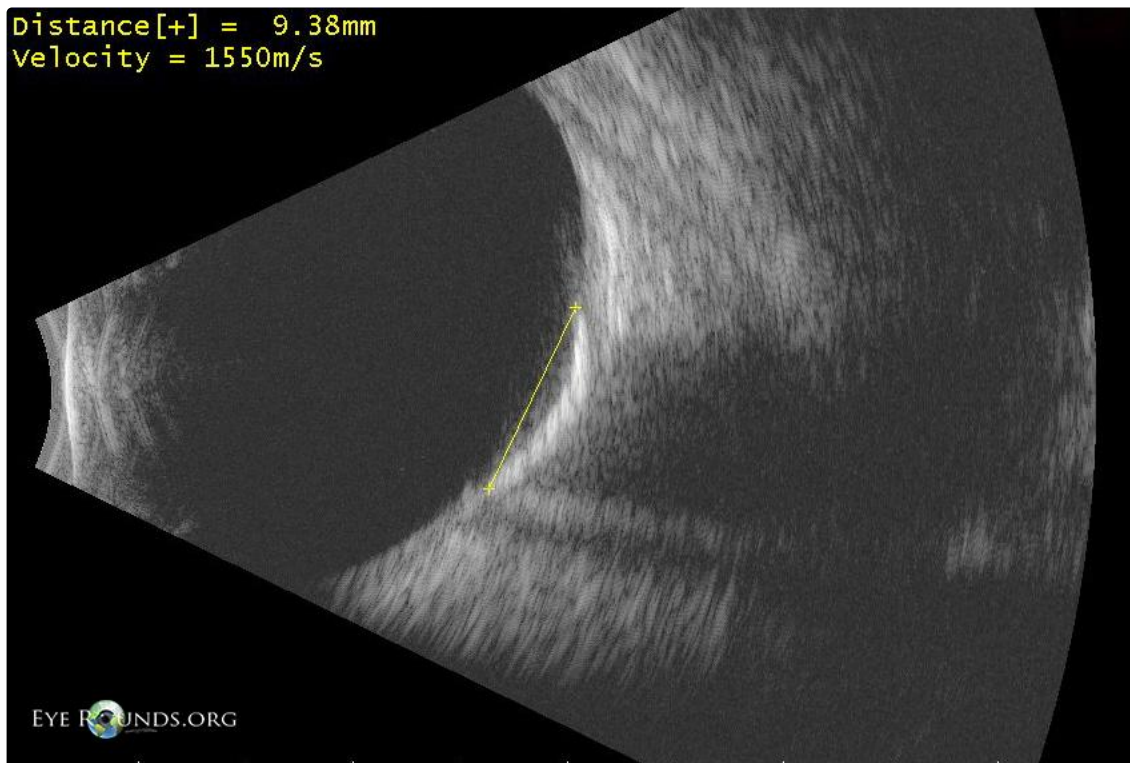


EYE ROUNDS.ORG

The A-scan shows the high reflectivity of the mass.

[Enlarge](#)

[Download](#)



Distance[+] = 9.38mm
Velocity = 1550m/s

EYE ROUNDS.ORG

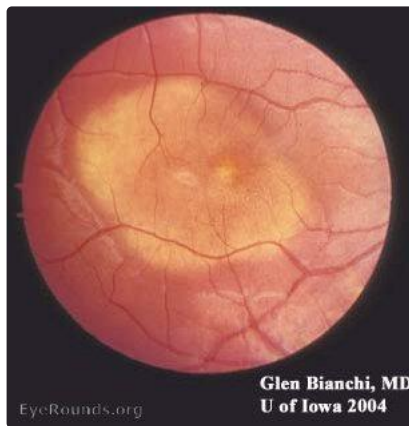The B-scan reveals the extent of the highly echogenic lesion and the associated acoustic shadowing which is characteristic for these tumors.

[Enlarge](#)

[Download](#)

Other choroidal osteoma images

Contributor: Glen Bianchi, MD and Andrew Doan, MD, PhD, University of Iowa

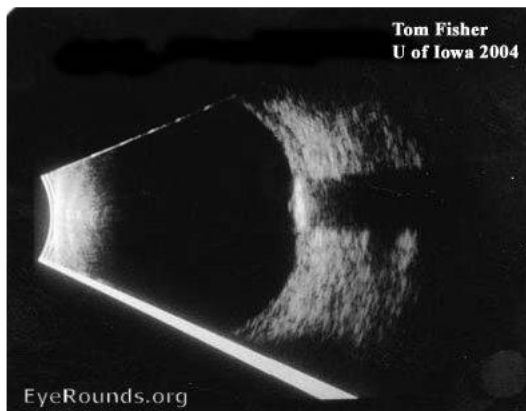

[Enlarge](#)

[Download](#)

Other choroidal osteoma images

Contributor: Andrew Doan, MD, PhD, and Tom Fisher, University of Iowa



Note shadowing on B-scan

[Enlarge](#)

[Download](#)

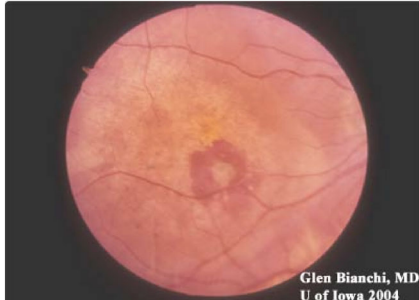Image Permissions:



Ophthalmic Atlas Images by EyeRounds.org, The University of Iowa are licensed under a [Creative Commons Attribution-NonCommercial-NoDerivs 3.0 Unported License](https://creativecommons.org/licenses/by-nc-nd/3.0/).



Related Articles



Glen Bianchi, MD
U of Iowa 2004

[Related Case: Choroidal Osteoma](#)

Address

University of Iowa
Roy J. and Lucille A. Carver College
of Medicine
Department of Ophthalmology and
Visual Sciences
200 Hawkins Drive
Iowa City, IA 52242

[Support Us](#)

Legal

Copyright © 2019 The University of
Iowa. All Rights Reserved
[Report an issue with this page](#)
[Web Privacy Policy](#) |
[Nondiscrimination Statement](#)

Related Links

[Cataract Surgery for Greenhorns](#)
[EyeTransillumination](#)
Gonioscopy.org
[Iowa Glaucoma Curriculum](#)
[Iowa Wet Lab](#)
[Patient Information](#)
[Stone Rounds](#)
[The Best Hits Bookshelf](#)

EyeRounds Social Media

Follow



Receive notification of new cases,
[sign up here](#)
[Contact Us](#)
[Submit a Suggestion](#)